Baruah *et al. Egyptian Liver Journal* (2023) 13:19
https://doi.org/10.1186/s43066-023-00253-z

Egyptian Liver Journal

ORIGINAL RESEARCH ARTICLE

Open Access

Histopathological categorization of desmoplastic reaction in gallbladder carcinoma: its relation to cancer invasiveness and prognostic utility

Abir Baruah[1], Geet Bhuyan[1*] and Projnan Saikia[1]

Abstract

Background Desmoplastic changes in a tumor have been observed to affect the tumor microenvironment, leading to both the facilitation and prevention of tumor invasiveness.

Methods Between 2016 and 2020, a total of 120 patients were diagnosed with gallbladder carcinoma. The cases were reviewed for the type of desmoplastic reaction, tumor grade, and stage. The type of desmoplastic reaction was classified as mature, intermediate, and immature, and they were correlated with tumor grade and stage.

Results Out of the total number of cases, 21.67%, 48.33%, 25%, and 5% belonged to stages 1, 2, 3, and 4, respectively. A total of 79.2% of these cases showed desmoplastic stromal reaction, and there was a significant correlation ($p < 0.05$) between the type of desmoplasia and tumor grade and stage. The occurrence of immature stroma was correlated with increasing tumor grade and stage, and occurrence of mature stroma was negatively correlated with increasing tumor grade and stage.

Conclusion The assessment of the type of stromal desmoplastic reaction in primary gallbladder carcinoma can predict the tumor invasiveness.

Keywords Gallbladder, Carcinoma, Desmoplasia, Prognosis, Invasiveness

Introduction

Primary carcinoma of the gallbladder is the 5th most common malignancy of the gastrointestinal tract, of which adenocarcinoma accounts for 75 to 85% of cases [1]. According to GLOBOCAN 2020, the total number of new cases of gallbladder carcinoma worldwide was 115,949, and the total number of deaths by gallbladder carcinoma was 84,695 [2]. India is a high incidence area for gallbladder cancer, contributing to about 10% of the global burden [3]. The prognosis of the disease is very poor and correlates with the stage of the disease at presentation [1]. A significant desmoplastic stromal reaction is seen in some gallbladder carcinomas [4].

Cancer cells are affected by various cells in the tumor microenvironment during invasion and metastasis [5]. One of the important cells contributing to this microenvironment favoring tumor invasion is the myofibroblasts in the cancer stroma [6]. They are responsible for the production of collagen and extracellular matrix that constitutes the desmoplastic reaction seen in cancer stroma. The various mechanisms proposed that result in myofibroblast activation includes immune cytokine mechanisms and microvasular injury with features analogous to wound healing and paracrine activation of myofibroblasts

*Correspondence:
Geet Bhuyan
geetbhuyan.aiims@gmail.com
[1] Department of Pathology, Jorhat Medical College and Hospital, Jorhat, Assam, India

by growth factors released by tumor cells. The various growth factors responsible for this stromal activation are transforming growth factors (TGF-α & TGF-β), insulin-like growth factors (IGF-I & IGF-II), and platelet-derived growth factors (PDGF), all secreted by cancer cells. In a xenograft model study conducted by Shao et al., it was seen that xenografts from breast tumors showing a marked desmoplastic response demonstrated stromelysin 3, tissue inhibitor of metalloproteinases (TIMP-I), and IGF-II and corresponded to grade 1 or grade 2 breast carcinoma, while non-desmoplastic xenografts represented cancers of higher histological grade [7]. DeFilippis et al. found that CD36 repression in cancer fibroblasts that is associated with increased ECM deposition may actually predate the development of malignancy. This may create a premalignant niche where the presence of a stiff collagen-rich matrix initiates signals through mechanosensors that affect the expression of genes involved in differentiation and malignancy [8]. Thus, desmoplastic changes may actually be a promoter of malignancy.

Fibrosis is a normal process associated with wound healing, and desmoplastic reactions with mature fibroblasts are generally associated with the inhibition of the spread of tumor cells [9, 10]. However, immature desmoplastic reactions with keloid-like collagen deposition are associated with the promotion of tumor infiltration [11, 12].

Thus, apart from tumor cell pathology, a study of stromal reactions is indispensable to a comprehensive understanding of gallbladder cancer growth and spread. Hence, the present study aims to evaluate the association between desmoplastic reaction pattern and cancer invasiveness in primary gallbladder carcinoma.

To our knowledge, only a few studies have discussed the relation between desmoplastic tumor response and cancer invasion, and this appears to be one of the first studies to evaluate this relationship in gallbladder carcinoma.

Material and methods

One-hundred and twenty patients with carcinoma of the gallbladder diagnosed during 2016–2020 in the Department of Pathology of Jorhat Medical College were included in the study. Patients with a previous history of radiotherapy or chemotherapy were excluded from the study. In every case, hematoxylin and eosin-stained sections were examined to assess tumor grade and tumor invasiveness and to categorize the desmoplastic reaction. Tumor invasiveness was ascertained by pTNM staging as per the American Joint Committee on Cancer (AJCC) 8th edition [13].

The stromal response to cancer cells was classified according to the dominant characteristics of stromal tissue. Tissue in which collagen and fibroblasts were predominantly distributed in the tumor matrix was classified as a desmoplastic reaction, and tissue in which inflammatory cells predominated was classified as an inflammatory reaction [10].

Criteria for histological categorization of fibrotic cancer stroma

Stromal assessment was done at the invasive front in sections containing the deepest level of invasion. Desmoplasia was considered to be as follows: (1) mature, when there were fine and elongated collagen fibers with spindle-shaped fibrocytes stratified into multiple layers; (2) intermediate when broadbands of collagen with brightly eosinophilic hyalinization, similar to those seen in a keloid, were intermingled with mature collagen fibers; and (3) immature when randomly oriented keloid-like collagen bundles were surrounded by loose stroma with plump fibroblasts. The final assessment was done based on the most immature stroma on a single 10 × field at the invasive front [14]. We allotted a score of 1, 2, and 3, respectively, for mature, intermediate, and immature desmoplasia for statistical calculations.

Statistical analysis

Statistical analysis was carried out using SPSS version 25 (IBM, USA) [15]. The chi-square statistic was used to assess the significance of the difference between the associations of variables such as cancer invasiveness and type of stromal desmoplastic reaction. Also, Spearman's rank correlation coefficient (ρ) was calculated to determine the correlation between tumor invasiveness (tumor grade and stage) and type of desmoplasia denoted by a score of 1–3.

Results

The ratio of male to female cases of gall bladder carcinoma in this study was approximately 1:1.9. Out of the 120 cases, 21.67%, 48.33%, 25%, and 5% belonged to stages 1, 2, 3, and 4, respectively. As regards tumor grade, 54.16% of the cases were grade 1, 34.16% were grade 2, and 11.67% were grade 3. It was observed in the data set that 40% of the cases had a purely desmoplastic reaction, 39.2% had both a desmoplastic and inflammatory reaction, and 20.8% had a purely inflammatory reaction. Out of the cases showing a desmoplastic reaction, 49.5% showed a mature desmoplastic reaction (Fig. 1), 34.7% showed an intermediate type of desmoplastic reaction (Fig. 2), and only 15.8% of cases showed an immature desmoplastic reaction (Fig. 3) (Table 1).

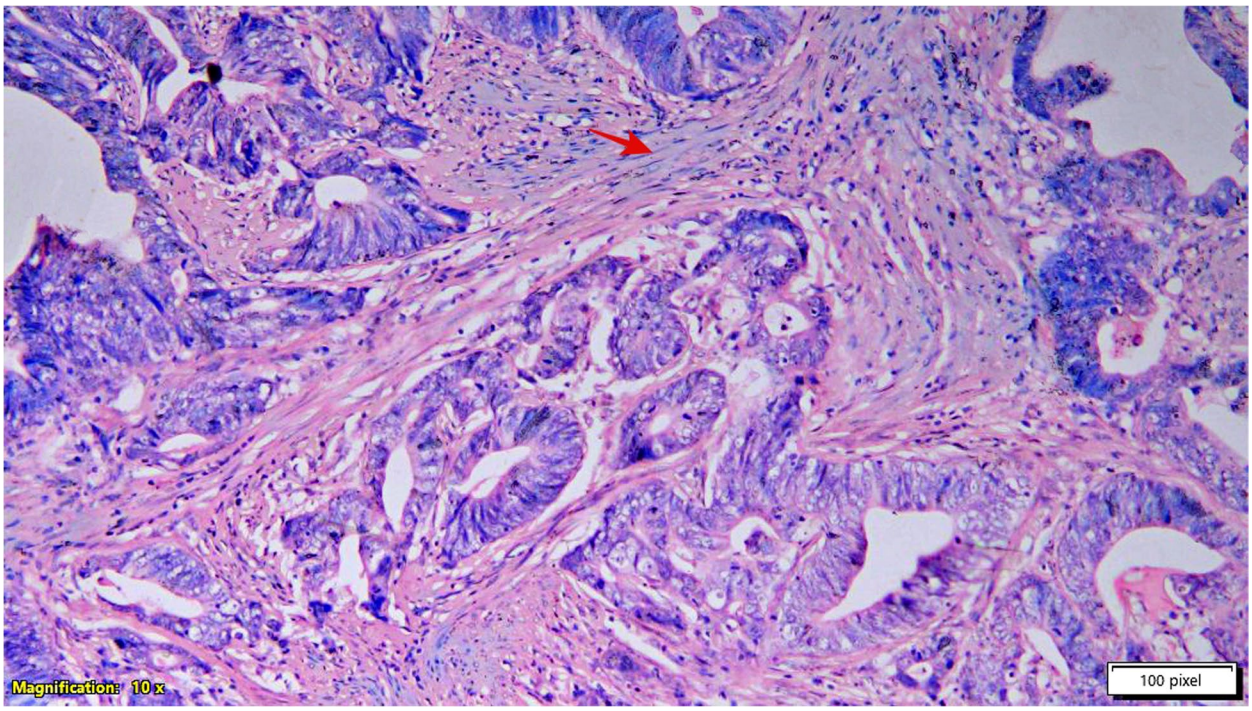

Fig. 1 Mature desmoplastic reaction. Invasion of tumor with surrounding collagen fibers with spindle-shaped fibrocytes stratified in multiple layers (red arrow) (H&E, 10 ×)

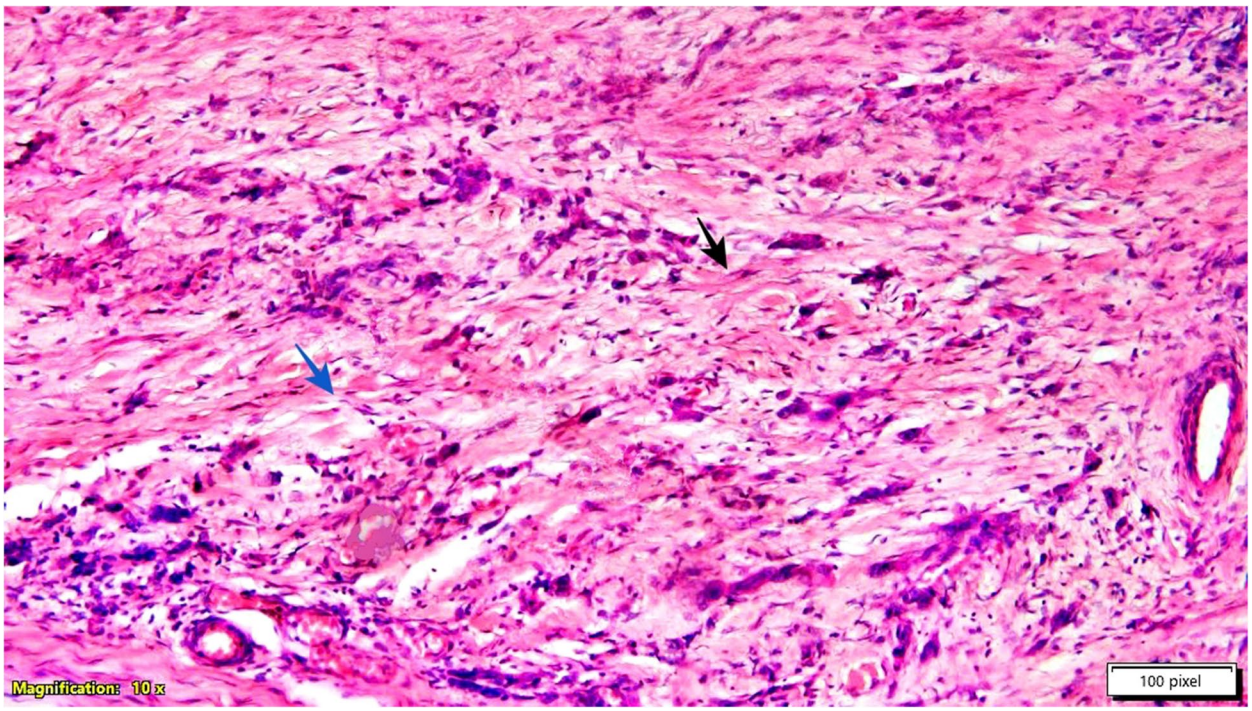

Fig. 2 Intermediate desmoplastic reaction. Broadbands of collagen with brightly eosinophilic hyalinization (black arrow) with mature collagen fibers and loose immature stroma (blue arrow) surrounding clusters of tumor cells (H&E, 10 ×)

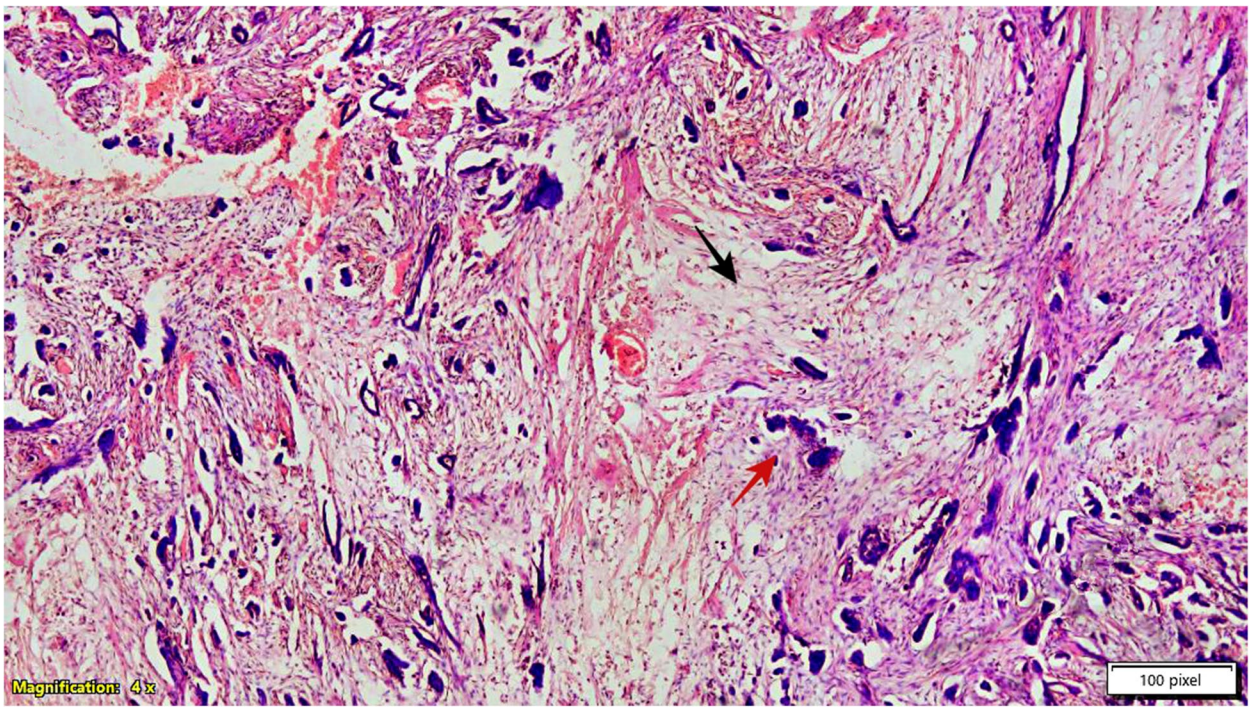

Fig. 3 Immature desmoplastic reaction. Loose stroma with plump fibroblasts (black arrow) with the presence of few cluster of poorly differentiated tumor cells (red arrow) (H&E, 4 ×)

Table 1 Distribution of cases according to type of stromal desmoplastic reaction

Type of desmoplastic reaction	Number of cases	Percentage
Mature	47	49.5
Intermediate	33	34.7
Immature	15	15.8
Total number of cases showing desmoplastic reaction	95	100

We tried to establish the relationship between tumor stage (as per AJCC) and type of desmoplasia, and it was found that the association between these two parameters was statistically significant ($p < 0.05$) (Table 2). The frequencies of immature stromal desmoplastic reaction in stages 1, 2, 3, and 4 were 5.9%, 12.2%, 26.1%, and 33.3%, respectively.

We studied the association between tumor grade and the type of desmoplasia, and it proved to be significant statistically ($p < 0.05$) (Table 3). Higher-grade tumor, grade 3, showed greater frequency of immature stromal desmoplastic reaction (78.6%), while grade 2 vs. grade 1 tumor showed 7.9% and 2.6%, respectively.

It was found that there was a significant positive correlation between advancing tumor stage and desmoplastic pattern score (1–3) [$\rho = 0.30031$, p (2-tailed) = 0.00311]. Similarly, there was a significant positive correlation between desmoplastic pattern score (1–3) and tumor grade [$\rho = 0.51804$, p (2-tailed) = 0] (Tables 2, 3) (Figs. 4, 5).

Table 2 Association between tumor stage (as per AJCC) and type of stromal desmoplastic reaction

TNM	Total cases showing desmoplastic reaction	Mature		Intermediate		Immature		*P*-value
		n	%	*n*	%	*n*	%	
1	17	12	70.6	4	23.5	1	5.9	< 0.05
2	49	28	57.2	15	30.6	6	12.2	
3	23	6	26.1	11	47.8	6	26.1	
4	6	1	16.7	3	50	2	33.3	
R-value			− 0.97874				0.988897199	

Table 3 Association between tumor grade and type of stromal desmoplastic reaction

Tumor grade	Total cases showing desmoplastic reaction	Mature		Intermediate		Immature		*P*-value
		n	%	*n*	%	*n*	%	
1	38	32	84.2	5	13.2	1	2.6	< 0.05
2	38	8	21	27	71	3	7.9	
3	14	2	14.3	1	7.1	11	78.6	
R-value			− 0.90618				0.895561626	

Discussion

Both an increase and a decrease in collagen, a major component of the extracellular matrix, have been linked to increased cancer invasiveness. In cancer (a process similar to wound healing), activated fibroblasts can simulate the normal wound healing process and thus function as a barrier to inhibit spread of cancer cells. However, an atypical wound healing process similar to keloid formation can promote tumor infiltration [12].

Ueno et al. [10] histologically subcategorized stromal desmoplastic reactions in rectal cancer as mature, intermediate and immature based on the properties of stromal collagen in the tumor area. Furthermore, they found that an immature type of desmoplastic reaction was associated with greater tumor invasiveness. To our knowledge, this is the first research piece to categorize the stromal desmoplastic reaction in primary gallbladder carcinoma and to study its association with tumor invasiveness. In our study, 79.2% of the cases showed a stromal desmoplastic reaction. Out of the cases showing a desmoplastic reaction, 49.5% showed a mature desmoplastic reaction, 34.7% showed an intermediate type of desmoplastic reaction, and only 15.8% of cases showed an immature desmoplastic reaction.

In the present study, it was observed that there was a strong association between the advancing tumor stage and the type of stromal desmoplastic pattern ($p < 0.05$). Moreover there was a significant positive correlation between advancing tumor stage and desmoplastic pattern score (1–3) [$\rho = 0.30031$, p (2-tailed) $= 0.00311$]. Thus, there was a greater frequency of mature stromal pattern in early-stage tumors and a greater frequency of immature stroma in late-stage tumors. This is in accordance with the conclusion of Wernicke et al. [16] that loose and myxoid stroma favor tumor invasion more as compared to dense and sclerotic stromal reactions. Thus, here lies the importance of assessing the pattern of stromal reaction in gallbladder carcinoma, which can give a fair prediction of both lymph nodal and distant metastases. It was found in the present study that there was a statistically significant association between tumor grade of gallbladder carcinoma and type of stromal desmoplasia ($p < 0.05$). It was observed that 84.2% of grade 1 tumors showed mature type of stromal desmoplasia,

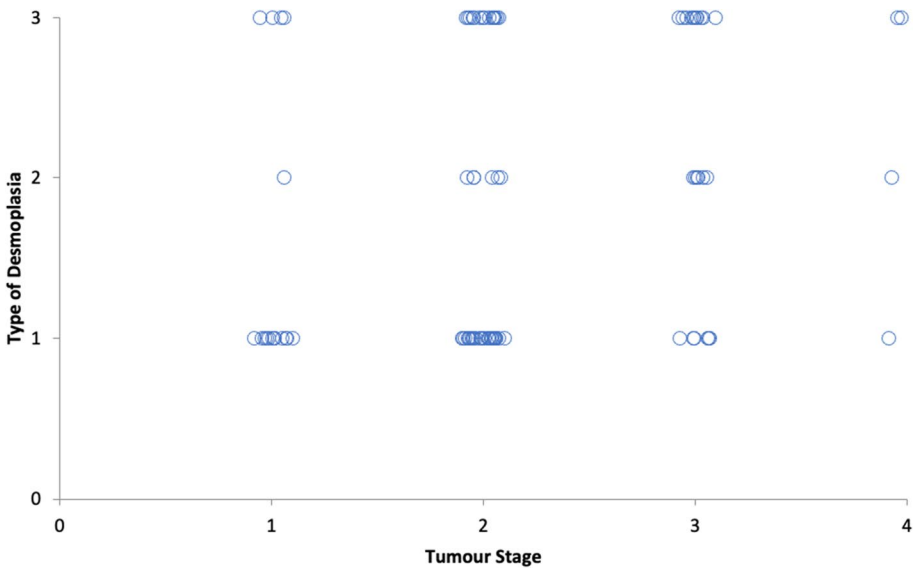

Fig. 4 Scatter plot showing correlation between tumor stage and stromal desmoplastic pattern

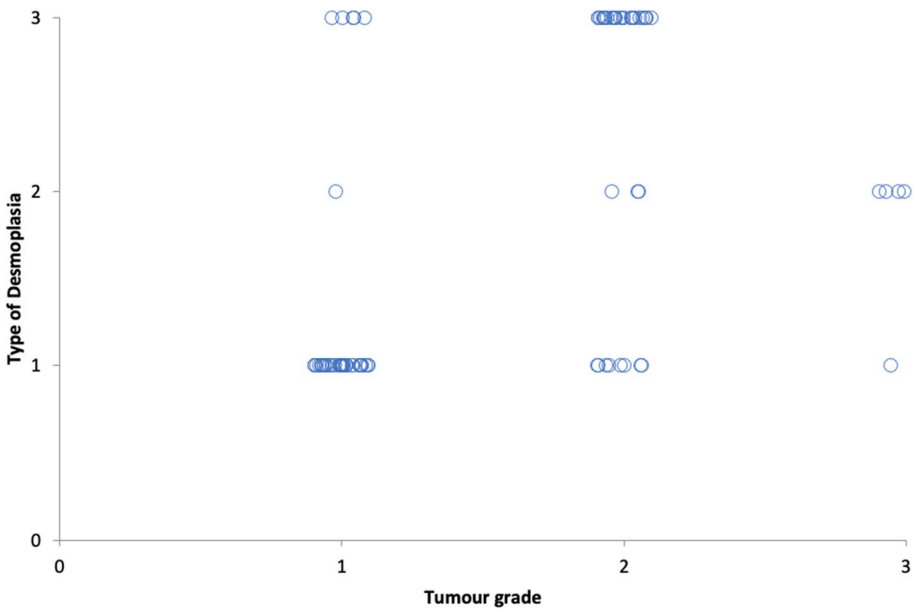

Fig. 5 Scatter plot showing correlation between tumor grade and stromal desmoplastic pattern (mature/immature)

72% of grade 2 tumors showed intermediate type of stromal desmoplasia, while 78.6% of grade 3 tumors showed immature type of stromal desmoplasia. Also, there was a significant positive correlation between desmoplastic pattern score (1–3) and tumor grade [$\rho = 0.51804$, p (2-tailed) = 0]. Thus, there was a greater frequency of mature stromal pattern in low-grade tumors and a greater frequency of immature stroma in high-grade tumors. As per Kalluri and Zeisberg (2006) and Karagiannis et al. (2012), cancer-associated fibroblasts (CAFs) in the tumor microenvironment aid in the dedifferentiation of carcinoma cells to undergo epithelial mesenchymal transition (EMT) [17, 18]. As per Ueno et al. (2002, 2004), the activities of these CAFs are related to the type of desmoplasia. This is because CAFs are also responsible for extracellular matrix remodelling [9–11]. Besides, these dedifferentiations of carcinoma cells brought about by EMT are related with the development of an advanced grade of cancer [19]. Thus, there is a correlation between tumor grade and type of stromal desmoplastic reaction, which is also evidenced in this study.

But is desmoplasia in cancer a double-edged sword? While the mature pattern of desmoplasia can inhibit tumor growth and metastasis, the tumor ECM, being more abundant, denser, and stiffer, can act as a barrier, shielding the cells from therapeutic agents. Thus, it may in turn be a deterrent to the action of anticancer drugs on tumor cells [20]. Saini et al. have further suggested the use of combination therapy using tranilast and doxorubicin to reduce the cancer stromal stiffness and result in better drug delivery [21].

Limitations

The study has several limitations. This includes a relatively small sample size and sampling done in a single institute. This has lower statistical impact, and thus, a larger sample size is required. Moreover, cancer-associated fibroblasts (CAFs) have to be studied at the molecular level for a better and definite understanding of their role in the process of tumor invasion and metastasis.

Conclusion

Hence, it can be concluded that assessment of the type of stromal desmoplastic reaction in primary gallbladder carcinoma can predict the tumor invasiveness. Moreover, it is important to study the type of stromal desmoplastic reaction in primary gallbladder carcinoma along with the morphology of epithelial component, as the former plays a great role in the tumor microenvironment and is associated with higher grade of the tumor and its invasiveness.

Authors' contributions

AKB, concept, design, literature search, data acquisition, manuscript preparation, data analysis, and manuscript editing and review. GB, concept, data acquisition, manuscript preparation, manuscript editing and review, and guarantor. The authors read and approved the final manuscript.

Funding

No funding sources.

Declarations

Ethics approval and consent to participate

This study protocol was reviewed and approved by Institutional Ethics Committee, Jorhat Medical College and Hospital, IEC(H) Reg. No. EC/NEW/INST/2020/1221. The study, being a retrospective study, will collect all patient-related data from the hospital medical records only. The study involves no more than minimal risk to the study subjects. Therefore, the institutional ethics committee, Jorhat Medical College and Hospital, has granted an exemption from requiring written informed consent for the study. (The study was reviewed and approved by Institutional Ethics Committee, Jorhat Medical College and Hospital, IEC(H) Reg. No. EC/NEW/INST/2020/1221.)

Competing interests

The authors declare that they have no competing interests.

Received: 15 December 2022 Accepted: 3 April 2023
Published online: 10 April 2023

References

1. Ferrel L, Kakar S (2013) Diagnostic histopathology of tumours. Chapter 10, Tumours of the liver, biliary tree, and gallbladder, 4th edn. Elsevier Saunders, Philadelphia, p 517
2. Globocan (2020) World Health Organisation https://gco.iarc.fr/today/data/factsheets/cancers/12-Gallbladder-fact-sheet.pdf
3. Dutta U, Bush N, Kalsi D, Popli P, Kapoor VK (2019) Epidemiology of gallbladder cancer in India. Chin Clin Oncol 8(4):33
4. Giang TH, Ngoc TT, Hassell LA (2012) Carcinoma involving the gallbladder: a retrospective review of 23 cases - pitfalls in diagnosis of gallbladder carcinoma. Diagn Pathol 7:10
5. Shi Y, Du L, Lin L, Wang Y (2017) Tumour-associated mesenchymal stem/stromal cells: emerging therapeutic targets. Nat Rev Drug Discov 16:35–52
6. Mehner C, Radisky DC (2013) Triggering the landslide: the tumor-promotional effects of myofibroblasts. Exp Cell Res 319(11):1657–1662
7. Walker RA (2001) The complexities of breast cancer desmoplasia. Breast Cancer Res 3(3):143–145
8. DeClerck YA (2012) Desmoplasia: a response or a niche? Cancer Discov 2(9):772–774
9. Ueno H, Kanemitsu Y, Sekine S, Ishiguro M, Ito E, Hashiguchi Y, Kondo F, Shimazaki H, Mochizuki S, Kaziwara Y, Shinto H, Yamamoto J (2017) Desmoplastic pattern at the tumour front defines poor-prognosis subtypes of colorectal cancer. Am J Surg Pathol 41:1506–1512
10. Ueno H, Shinto E, Shimazaki H, Kajiwara Y, Sueyama T, Yamamoto J (2015) Histologic categorization of desmoplastic reaction: its relevance to the colorectal cancer microenvironment and prognosis. Ann Surg Oncol 22:1504–1512
11. Ueno H, Jones AM, Wilkinson KH, Jass JR, Talbot IC (2004) Histological categorization of fibrotic cancer stroma in advanced rectal cancer. Gut 53:581–586
12. Ueno H, Jones A, Jass JR, Talbot IC (2002) Clinicopathological significance of the 'keloid-like' collagen and myxoid stroma in advanced rectal cancer. Histopathology 40:327–334
13. Amin MB, Greene FL, Edge SB, Compton CC, Gershenwald JE, Brookland RK, Meyer L, Gress DM, Byrd DR, Winchester DP (2017) The Eighth Edition AJCC Cancer Staging Manual: continuing to build a bridge from a population-based to a more "personalized" approach to cancer staging. CA Cancer J Clin 67(2):93–99
14. Amano Y, Kihara A, Hasegawa M, Miura T, Matsubara D, Fukushima N (2022) Clinicopathological and prognostic significance of stromal patterns in oral squamous cell carcinoma. Front Med 9:859144
15. IBM Corp (2017) BM SPSS Statistics for Windows, version 25.0. IBM Corp. - References - Scientific Research Publishing, Armonk. Available from: https://www.scirp.org/reference/ReferencesPapers.aspx. Cited 2023 Feb 8. ReferenceID=2363614
16. Wernicke M, Piñeiro LC, Caramutti D, Dorn VG, Raffo MM, Guixa HG, Telenta M, Morandi AA (2003) Breast cancer stromal myxoid changes are associated with tumour invasion and metastasis: a central role for hyaluronan. Mod Pathol 16(2):99–107
17. Kalluri R, Zeisberg M (2006) Fibroblasts in cancer. Nat Rev Cancer 6(5):392–401
18. Karagiannis GS, Poutahidis T, Erdman SE, Kirsch R, Riddell RH, Diamandis EP (2012) Cancer-associated fibroblasts drive the progression of metastasis through both paracrine and mechanical pressure on cancer tissue. Mol Cancer Res 10(11):1403–1418
19. Teschendorff AE, Journee M, Absil PA, Sepulchre R, Caldas C (2007) Elucidating the altered transcriptional programs in breast cancer using independent component analysis. PLoS Comput Biol 3:e161
20. Henke E, Nandigama R, Ergün S (2020) Extracellular matrix in the tumour microenvironment and its impact on cancer therapy. Front Mol Biosci 6:160
21. Saini H, RahmaniEliato K, Silva C, Allam M, Mouneimne G, Ros R (2018) The role of desmoplasia and stromal fibroblasts on anti-cancer drug resistance in a microengineered tumour model. Cell Mol Bioeng 11(5):419–433

Publisher's Note