



CASE REPORT

Open Access



# Multiple biliary hamartomas “von Meyenberg complexes” in a newborn: a unique observation

Moaied A. Hassan 

## Abstract

**Background:** Biliary hamartomas are rare benign bile duct malformations consisting of multiple collections of localized duct-like structures that are lined by biliary epithelium and embedded in a fibrous stroma. In general, these malformations are asymptomatic and are usually detected incidentally during imaging, surgical exploration, or autopsy. Previously, the definitive diagnosis of these lesions was possible only with liver biopsy. The use of advanced imaging modalities made it possible to establish the diagnosis when undoubtful imaging findings are evident.

**Case presentation:** We present a 25-day-old male newborn who was referred to our institution with jaundice, abdominal distension, and abdominal U/S that revealed hepatomegaly and involvement of both lobes of the liver with diffuse cystic lesions of variable sizes and echogenicity without a diagnostic suggestion. We discuss the details of imaging findings that enabled to establish the diagnosis of multiple biliary hamartomas and brief the patient's status on follow-up.

**Conclusion:** Up to our best knowledge, the diagnosis of multiple biliary hamartomas has not been previously reported among newborns, making this report an extremely rare if not a unique observation.

**Keywords:** Biliary hamartomas, Liver, von Meyenburg complexes, Newborn

## Background

Biliary hamartomas are rare benign bile duct malformations consisting of multiple collections of localized duct-like structures that are lined by biliary epithelium and embedded in a fibrous stroma [1]. Hanns von Meyenburg, a Swiss pathologist, was the first to describe these lesions in 1918, and because of that are referred to as von Meyenberg complexes [2]. Interrupted remodeling of the ductal plates during late embryonic development of the intrahepatic bile ducts is thought to be responsible for the development of these malformations [3]. The incidence of biliary hamartomas is very low and has been estimated at 0.69–5.6% in autopsy series, and 0.6% in needle biopsy series [4]. In general, these

malformations are asymptomatic and are usually detected incidentally during imaging, surgical exploration, or autopsy [5]. The clinical significance of biliary hamartomas lies in their propensity to be easily confused with liver metastasis, Caroli's disease, microabscesses, and other cystic hepatic lesions, along with their possible malignant transformation into cholangiocarcinoma [1]. Previously, the definitive diagnosis of these lesions was possible only with liver biopsy. The use of advanced imaging modalities made it possible to establish the diagnosis when undoubtful imaging findings are evident [1]. Herein, we present the extremely rare and possibly unique occurrence of diffuse multiple biliary hamartomas in a 25-day-old newborn.

Correspondence: [moaied70@yahoo.com](mailto:moaied70@yahoo.com)

Pediatric Surgery Department, Basrah Children's Specialty Hospital, Basrah, Iraq



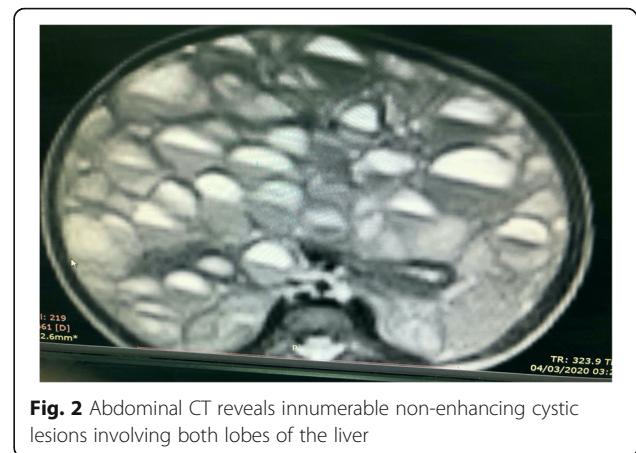
© The Author(s). 2020 **Open Access** This article is licensed under a Creative Commons Attribution 4.0 International License, which permits use, sharing, adaptation, distribution and reproduction in any medium or format, as long as you give appropriate credit to the original author(s) and the source, provide a link to the Creative Commons licence, and indicate if changes were made. The images or other third party material in this article are included in the article's Creative Commons licence, unless indicated otherwise in a credit line to the material. If material is not included in the article's Creative Commons licence and your intended use is not permitted by statutory regulation or exceeds the permitted use, you will need to obtain permission directly from the copyright holder. To view a copy of this licence, visit <http://creativecommons.org/licenses/by/4.0/>.

### Case presentation

A 25-day-old male newborn was referred to our institution with jaundice, abdominal distension, and abdominal U/S that revealed hepatomegaly and involvement of both lobes of the liver with diffuse cystic lesions of variable sizes and echogenicity without a diagnostic suggestion (Fig. 1). Blood counts and morphology tests were within normal limits apart from hypochromic microcytic anemia. The liver function test revealed indirect hyperbilirubinemia [102 mmol/L], with elevated serum alkaline phosphatase [761 U/L] and serum glutamic-oxaloacetic transaminase [72 U/L] levels, hypoproteinemia [47 G/L], and hypoalbuminemia [24 G/L]. TORCH screen was negative, prothrombin, and partial thromboplastin times, and blood urea and serum creatinine levels were all within normal limits.

Abdominal CT revealed the presence of diffuse, innumerable, non-communicating, and non-enhancing cystic lesions involving both lobes of the liver, with the largest cyst measuring 22 × 22 mm at the left lobe segment II, with the diagnosis of multiple biliary hamartomas (Fig. 2). Abdominal MRI revealed markedly enlarged liver [liver span=140 mm], with the liver parenchyma being replaced by non-communicating, cystic lesions of variable sizes, hyperintense at T2-weighted images giving the characteristic starry sky appearance of multiple biliary hamartomas (Fig. 3). The possibility of Caroli's disease has been excluded as these cysts shown only marginal enhancement with no significant internal enhancement.

The baby's anemia and hypoalbuminemia were corrected with blood and albumin transfusion, respectively. His general condition and vital signs were satisfactory. The family was instructed that their baby suffers an extremely rare developmental malformation of the bile ducts that mandates close clinical and imaging follow-up with special concern on the function of the liver and that surgical excision is not an option as the whole liver is



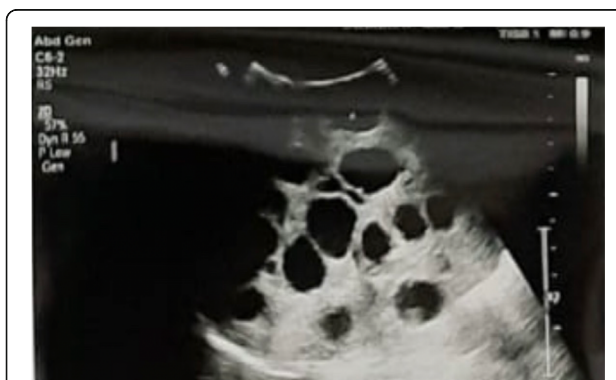
**Fig. 2** Abdominal CT reveals innumerable non-enhancing cystic lesions involving both lobes of the liver

replaced by these lesions considering liver transplantation in the future. So far, the baby has been followed-up closely for 4 months. The baby is now jaundice-free, liver function test is within normal limits, imaging studies reveal no significant changes, and he suffers no significant medical problems.

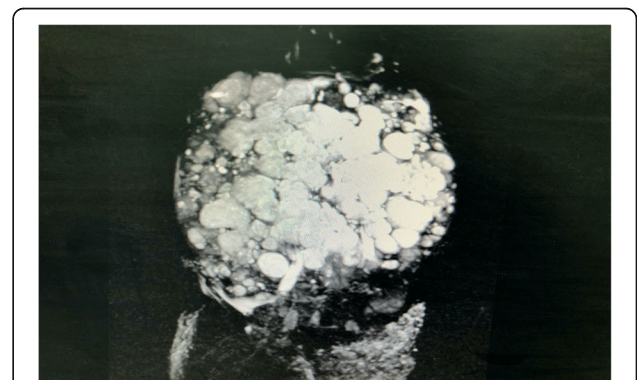
### Discussion

Biliary hamartomas are rare benign bile duct malformations consisting of focal collections of dilated intrahepatic bile ducts embedded within a dense collagenous stroma. These lesions are usually small (< 5 mm in diameter), typically multiple and scattered throughout both lobes of the liver. Some may aggregate to appear as large solitary lesions on imaging studies [5].

Biliary hamartomas are generally asymptomatic, although abdominal enlargement, jaundice, and portal hypertension may arise as a result of mass effect [6, 7]. Being small-sized and asymptomatic, these lesions are usually detected incidentally during imaging, surgical exploration, or autopsy.



**Fig. 1** Abdominal U/S reveals diffuse involvement of the liver with hypoechoic cystic lesions of variable sizes



**Fig. 3** Abdominal MRI reveals hyperintense cystic lesions replacing the liver parenchyma "Starry sky appearance"

The patient reported in this study is a 25-day-old newborn, and “up to our best knowledge,” the diagnosis of multiple biliary hamartomas has not been previously reported among newborns, making this report an extremely rare if not a unique observation. Makhneva et al. described multiple biliary hamartomas in a 3-year-old child [7]. Jaundice and abdominal distension were the alarming signs in the reported newborn patient that brought the attention of the attending pediatrician to request an abdominal ultrasound which revealed the presence of multiple cystic lesions in the liver.

Technical advances in imaging modalities have made the detection of these malformations easy. Biliary hamartomas show characteristic features on imaging studies, and accurate diagnosis can be established when typical undoubtful features are evident obviating the need for a liver biopsy which should be performed only to confirm the diagnosis when in doubt [5, 8].

On sonography, biliary hamartomas have been described to appear as innumerable small hypoechoic or hyperechoic lesions measuring less than 10 mm and uniformly distributed throughout the liver, and may have a comet tail artifact. Variability in echogenicity reflects differences in the size of the dilated bile duct components, which, at a certain size, will show echogenicity as they behave like other microcystic structures, and below it, their complex internal structure might reflect poor echogenicity [3].

On contrast-enhanced CT, the majority of the reported cases of biliary hamartomas did not show contrast enhancement. This observation might reflect the poor vascularity of these lesions described on histology [4, 6].

On MRI, biliary hamartomas have been described to appear as hypointense lesions on T1-weighted images. On T2-weighted images, they appear hyperintense when compared with surrounding liver parenchyma giving the characteristic starry sky appearance [4, 9].

The imaging findings of the patient presented in this report were consistent with those reported in the literature; hence, the diagnosis was confirmed radiologically without the need to perform liver biopsy taking into consideration the necessity of long-term clinical and imaging follow-up.

The baby presented in this study was exclusively breastfed, and this may represent the best available explanation for the elevated liver enzymes in the presence of indirect hyperbilirubinemia. Several studies have reported elevated liver enzymes in breastfed babies with indirect hyperbilirubinemia and suggested that those findings might be the result of mild and transient hepatic dysfunction or cholestasis that resolve over time [10, 11]. Resolution of jaundice and returning of liver enzymes to their normal levels in the presented patient

who is still having his pathology in place, the fact that the majority of multiple biliary hamartomas are asymptomatic along with the unavailability of previous studies that report similar pathology in newborns makes us support this explanation. Further studies and observations may provide better insight for this finding in the future.

The clinical significance of biliary hamartomas lies in their propensity to be easily confused with liver metastasis, Caroli's disease, microabscesses, and other cystic hepatic lesions, along with their possible malignant transformation into cholangiocarcinoma. The patient reported in this study is a newborn; besides, the lesions did not show enhancement on CT after the administration of IV contrast which excluded the possibility of dealing with a case of liver secondaries. Caroli's disease was excluded as the lesions did not show the “central dot” sign of central enhancement on MRI. A close and long-term clinical and imaging follow-up is required, with the possibility of performing liver biopsy when indicated to exclude other possible pathologies.

## Conclusion

Biliary hamartomas are rare benign bile duct malformations resulting from the interrupted remodeling of the ductal plates during the late embryonic development of the intrahepatic bile ducts. We report the diagnosis of these rare malformations in a newborn baby, and up to our best knowledge, the diagnosis of multiple biliary hamartomas has not been previously reported among newborns, making this report an extremely rare if not a unique observation.

## Acknowledgements

Not applicable.

## Author's contributions

The author(s) read and approved the final manuscript.

## Funding

None.

## Availability of data and materials

Not applicable.

## Ethics approval and consent to participate

Written informed consent to participate was obtained from the parent.

## Consent for publication

Written informed consent for publication of this case report and accompanying images was obtained from the parent.

## Competing interests

The author declares that he has no competing interests.

Received: 16 June 2020 Accepted: 18 August 2020

Published online: 01 September 2020

## References

1. Teng SL, Shin JS, Huang JC (2015) An unusual polynodular liver disease: multiple biliary hamartoma. *Advances in Digestive Medicine* 2(1):37–40

2. Singh Y, Cawich SO, Ramjit C, Naraynsingh V (2016) Rare liver tumor: symptomatic giant von Meyenburg complex. *Journal of Surgical Case Reports* 11:1–4
3. Markhardt BK, Rubens DJ, Huang J, Dogra VS (2006) Sonographic features of biliary hamartomas with histopathologic correlation. *J Ultrasound Med* 25: 1631–1633
4. Zheng RQ, Zhang B, Kudo M, Onda H, Inoue T (2005) Imaging findings of biliary hamartomas. *World J Gastroenterol* 11:6354–6359
5. Jáquez-Quintana JO, Reyes-Cabello EA, Bosques-Padilla FJ (2017) Multiple biliary hamartomas, the “von Meyenburg complexes”. *Ann Hepatol* 16(5): 812–813
6. Barboi OB, Moisii LG, Albu-Soda A, Ciortescu I (2013) Drug V: biliary hamartoma. *Clujul Med* 86:383–384
7. Makhneva A, Aigul B, Minira B, Gauhar A (2015) Child's von Meyenburg complexes. *J Histol Histopathol* 2:15
8. Liu S, Zhao B, Ma J, Li J, Li X (2014) Lesions of biliary hamartomas can be diagnosed by ultrasonography, computed tomography and magnetic resonance imaging. *Int J Clin Exp Med* 7(10):3370–3377
9. Taguchi T, Kohsaki T (2020) “Starry sky” appearance from multiple biliary hamartomas. *N Engl J Med* 382(16):e33
10. Wu T-Z, Huang I-F, Chen Y-C, Chen P-H, Yang L-Y (2011) Differences in serum biochemistry between breast-fed and formula-fed infants. *J Chin Med Assoc* 74:511–515
11. Tazawa Y, Abukawa D, Watabe M et al (1991) Abnormal results of biochemical liver function tests in breast-fed infants with prolonged indirect hyperbilirubinaemia. *Eur J Pediatr* 150:310–313

## Publisher's Note

Springer Nature remains neutral with regard to jurisdictional claims in published maps and institutional affiliations.

**Submit your manuscript to a SpringerOpen<sup>®</sup> journal and benefit from:**

- Convenient online submission
- Rigorous peer review
- Open access: articles freely available online
- High visibility within the field
- Retaining the copyright to your article

---

Submit your next manuscript at ► [springeropen.com](https://www.springeropen.com)